



PRESENTING CLINICAL SIGNS

DATE History: New murmur. Asymptomatic.

10/21/22 **ECHOCARDIOGRAPHIC FINDINGS**
2D, M-mode, and Doppler study.

PERFORMED BY: There is mild left atrial dilation. The mitral valve leaflets are thickened and exhibit systolic prolapse. There is Doppler evidence of mitral regurgitation present. There is mild left ventricular dilation. Left ventricular systolic function is hyperdynamic. The aorta and aortic valve are normal. Right atrial and right ventricular dimensions are normal. The tricuspid valve is normal. The pulmonary artery and pulmonic valve are normal. No shunting lesions are visualized. No pericardial effusion or cardiac masses are seen.

Dr. Meredith Swart

INTERPRETED BY

Keith Blass, DVM,
MS, DACVIM
(Cardiology)

LA - 29.3 mm
LVIDd - 30.3 mm
LVIDs - 14.2 mm
FS - 53%
LVOT - 1.14 m/s
RVOT - 0.92 m/s

PATIENT

Annabelle Obee

ASSESSMENT/RECOMMENDATIONS
Degenerative mitral valve disease

SPECIES

Canine

This examination demonstrates regurgitation of blood across Annabelle's mitral valve resulting from degenerative valve disease. Secondary to her regurgitation, Annabelle has mild dilation of both her left atrium and left ventricle, though her left ventricular systolic function is well-preserved. As only mild left heart chamber dilation is present, Annabelle's current risk for the development of clinical signs secondary to her disease, such as coughing, exercise intolerance, syncope, and labored breathing, does not appear to be significantly increased, though careful monitoring for these signs is recommended going forward.

BREED

Yorkie

I recommend starting Annabelle on pimobendan (1.25 mg BID), as this medication should help to slow the progression of her mitral valve disease.

SEX

FS

A recheck echocardiogram is recommended in 9 months. Thoracic radiographs are recommended if Annabelle experiences respiratory clinical signs.

AGE

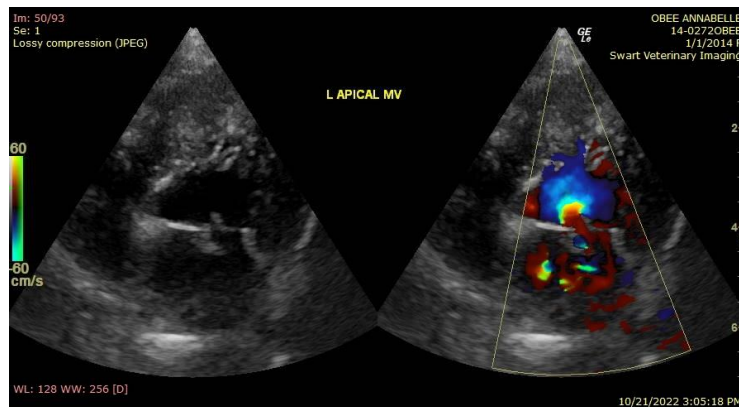
8 y

WEIGHT

12.6 lb

HOSPITAL NAME

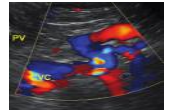
Swart Veterinary
Imaging



REFERRING VET

Dr. Swart

The information and recommendations provided are based on the images presented by the referring veterinarian. No evaluation can be communicated regarding pathology that was not



visible in the image/video clips provided.

DATE

10/21/22

Thank you for this referral. If the clinical or image interpretation does not parallel your findings or if I can be of any further assistance please contact me.

PERFORMED BY:

Keith Blass, DVM, MS, DACVIM (Cardiology)
KeithBlass@gmail.com
631-804-5754

Dr. Meredith Swart

INTERPRETED BY

Keith Blass, DVM,
MS, DACVIM
(Cardiology)

PATIENT

Annabelle Obee

SPECIES

Canine

BREED

Yorkie

SEX

FS

AGE

8 y

WEIGHT

12.6 lb

HOSPITAL NAME

Swart Veterinary
Imaging

REFERRING VET

Dr. Swart